

Carol Rees Parrish, MS, RDN, Series Editor

Auto-Brewery Syndrome: A Schematic for Diagnosis and Appropriate Treatment



Fahad Malik



Prasanna Wickremesinghe



Atif Saleem

Auto-Brewery Syndrome (ABS), also called Gut Fermentation Syndrome, is a rare, underdiagnosed medical condition. This is caused by fermentation of ingested carbohydrate by gut fungi resulting in endogenous production of ethanol. Though this syndrome has been described in the medical literature for over 50 years, it still remains misunderstood with limited information regarding diagnosis and treatment. The presenting symptoms and signs of ABS can be protean and mimic other clinical entities. This can make diagnosing this condition challenging. We propose the following schematic for diagnosing and treating this unusual entity based on our ongoing study of ABS patients. The initial step in confirming this diagnosis is a standardized carbohydrate challenge test which we have devised and studied in our ongoing cohort of ABS patients.

INTRODUCTION

Auto-Brewery Syndrome (ABS), which has also been described as Gut Fermentation Syndrome, is a rare, underdiagnosed medical condition. In this condition, fermentation of ingested carbohydrate results in endogenous production of ethanol. This syndrome was originally described in 1946 in a 5-year-old South African child undergoing

Fahad Malik, MD Gastroenterology Fellow, United Health Services Wilson Medical Center, Department of Gastroenterology, Johnson City, NY Prasanna Wickremesinghe, MD, FACP, FACG, Gastroenterologist, Richmond University Medical Center, Department of Gastroenterology, Staten Island, NY Atif Saleem, MD Associate Program Director, United Health Services Wilson Medical Center, Department of Gastroenterology, Johnson City, NY

emergency laparotomy, during which a 3-inch posterior stomach wall tear was detected and alcohol noted in the stomach.¹ Multiple cases of ABS were subsequently described in Japan during the 1970s. In these cases, identified yeast forms were mostly *Candida* species as the causative agent.² ABS is more common in patients with chronic medical conditions such as diabetes, inflammatory bowel disease (Crohn's disease patients with strictures), short bowel syndrome or immunosuppressed subjects. Since then, there have been sporadic case reports of ABS worldwide.³⁻⁷ ABS can also occur in healthy individuals. In our cohort of ABS patients prior exposure to antibiotics was universal. Antibiotics can alter the gut microbiome allowing fungal elements to proliferate.^{8,9} Nonetheless, this condition has continued to be regarded as a myth

due to limited knowledge on the subject. Initially, only fungi were implicated in the conversion of carbohydrate to alcohol, but a recent large Chinese study also identified certain species of high alcohol-producing bacteria (e.g., *Klebsiella species*).¹⁰

Pathophysiology

Although the initiating or triggering factors resulting in ABS remain uncertain, we propose the following in its causation:

- 1. Alteration of the gut microbiome:** The disruption of gut homeostasis resulting in overgrowth of fungi, and in rare cases, high alcohol-producing bacteria (e.g., *Klebsiella species*).^{1,10} All of our patients had prior exposure to antibiotics before developing ABS symptoms.
- 2. Fungal fermentation:** Commercially, *Saccharomyces cerevisiae* (i.e., brewer's yeast) has been used for manufacturing beer for centuries.¹¹

Risk Factors

In our ABS cohort of patients, the most common risk factor for its causation has been prior use of antibiotics. Antibiotics may have disrupted the fine homeostatic balance and symbiotic relationship between the different types of gut microbiota causing yeast overgrowth. Several patients with diabetes, short bowel syndrome, intestinal bacterial overgrowth, and inflammatory bowel disease (Crohn's disease with strictures), have also been described with ABS. Healthy patients may also suffer from ABS if exposed to a precipitating cause.^{1,4,5-7,12} It is uncertain if any genetic components could have predisposed these patients to ABS.

Symptoms

Patients with ABS are known to present with signs and symptoms of inebriation. Some with psychiatric symptoms (i.e. altered mood, anxiety, dysphoria, changes in affect and depression) or neurological symptoms (i.e. changes in mental status, drowsiness, brain fog, seizures, and ataxia). The patients can also have the smell of alcohol on their breath. The effects of alcohol are the same regardless of whether it is endogenously or

exogenously derived, and can increase the risk of fatty liver, cirrhosis of the liver and acute or chronic pancreatitis.¹⁰ The legal limit for driving while intoxicated (DWI) is 0.08% in New York and many other states. We have encountered many patients with ABS with 3-4 times this level. These symptoms could also overlap with those of chronic fatigue syndrome, depression, and alcoholism itself.

Diagnosis

Usually, these patients are either identified by a concerned family member or had been arrested for alleged "DWI". Identifying these patients is difficult as ABS symptoms could masquerade as other entities. The medico-legal implications of DWI are self-evident. When investigating a patient with possible ABS, a complete medical history and a physical examination should be augmented with interrogation of family and friends as they may provide additional vital information. The patient can develop "memory fog" and therefore might have poor recall of past events. Particular attention should be paid to the onset of the condition, inciting factors, prior antibiotic use, mold exposure, and any other useful information available from their previous evaluations. Needless to say, the present or past detailed history of alcohol intake is mandatory, including asking when the patient last drank alcohol, if at all.

Basic laboratory tests, i.e. complete blood count, comprehensive metabolic panel, and stool testing should be performed to rule out other medical conditions (e.g. diabetes, immunosuppression, leukopenia). It is also important to ascertain that the patient is not surreptitiously drinking. Therefore, ideally the validity of the patient's denial of alcohol consumption has to be corroborated by a family member or a friend. The diagnosis of ABS can only be considered after other conditions which may present with similar symptoms have been ruled out. These patients are advised to purchase a breathalyzer and keep a log of their breathalyzer-measured breath alcohol content (BAC) morning and evening, and at any time when they are symptomatic. Any positive level of breathalyzer BAC measurement needs to be confirmed with a concomitant blood alcohol level and the patient's physician should also be immediately informed.

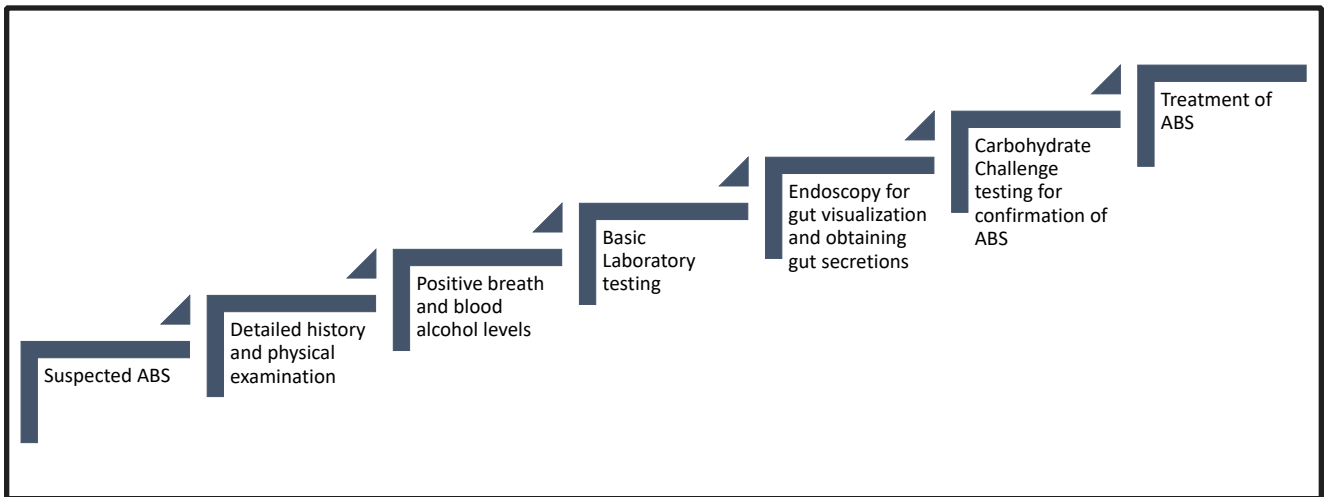


Figure 1. Stepwise Diagnostic Evaluation for Auto-Brewery Syndrome

Just prior to the carbohydrate challenge test, we initially perform upper and lower endoscopy to obtain gastric, upper small bowel, terminal ileal, and colon secretions. These samples are then tested for pH, gram stain, culture, and antibiotic and antifungal sensitivity in a commercial laboratory. Once a particular fungal species is identified, further antifungal sensitivity testing is conducted to determine the appropriate choice of subsequent therapy. The stepwise process for ABS diagnosis is summarized in Figure 1.

The carbohydrate challenge test should be performed when the patient's breath and blood alcohol levels are zero. If elevated, the patient will have to wait until it becomes zero prior to testing. Patients have to be under complete observation with no access to alcohol along with zero initial blood alcohol level in order for this test to be performed. A diagnostic standardized carbohydrate challenge test was performed after upper and lower endoscopic evaluation. This test consisted of administering 200g of glucose orally in a supervised setting in an isolation room and testing both breath and blood alcohol levels at baseline (0) and at 0.5, 1, 2, 4, 8 hours after glucose administration. Patient were allowed to eat any meal of their choice after the ingestion of 200g of oral glucose. If alcohol levels are elevated at any time during this evaluation, the test is aborted and considered to be positive. Patients who are still negative at 8 hours are given the option to return for a collection of a 16- and 24-hour sample as some fungi can take longer

than 8 hours to ferment carbohydrate. Therefore, a negative 8 hour test cannot exclude this diagnosis due to some fermentation occurring even after 24 hours.

Testing a stool sample can assist in the screening process, but the lower gastrointestinal tract can contain small amounts of fungal colonization which would be considered normal and fermentation here would have little clinical significance. Upper gastrointestinal tract fungal colonization is significant, as the presence of fungi is considered pathological in this location. All of the patients who are currently under treatment for ABS had a positive carbohydrate challenge test and positive stool mycological studies on gut secretions.

PRACTICAL GASTROENTEROLOGY

Visit our Website:

practicalgastro.com

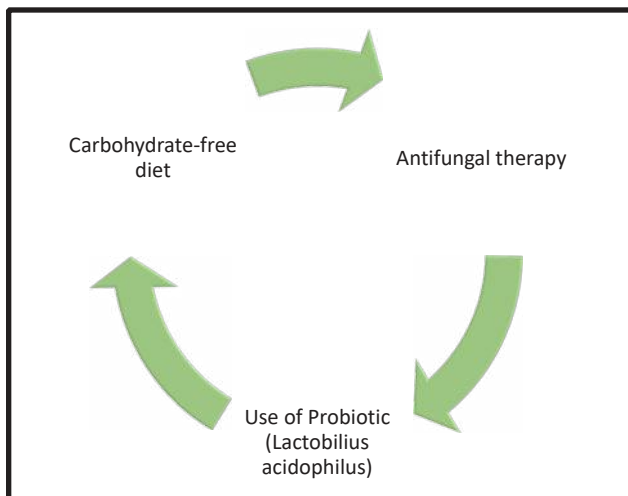


Figure 2. Algorithm for the Treatment of Auto-Brewery Syndrome

Until now there had been no known standardized screening test for ABS. Therefore sensitivity and/or specificity of this test is unstudied. We are the first to propose a carbohydrate challenge test to identify ABS patients. If BAC or blood alcohol is negative, it is unlikely to see a positive carbohydrate challenge test, even if there is a strong suspicion for ABS. When this carbohydrate challenge test is accepted and used more widely, we would have a better idea of the sensitivity, specificity and validity of this test. In our literature review, we have found less than 100 cases since 1952. We are now studying these patients and might be able provide more statistical information in the future.

Treatment

The same initial treatment protocol used for exogenous alcohol intoxication should be used to treat ABS patients as well. This would include administering appropriate intravenous fluids for hydration, maintaining a clear airway, and correcting calorie and nutritional deficiencies (folate and thiamine). Alcohol withdrawal symptoms if present should also be managed with benzodiazepines. After the resolution of the patient's acute symptoms and stabilization of the patient's condition, targeted treatment for the patient's ABS can be initiated. An interdisciplinary approach is strongly recommended in these situations with the assistance of a Gastroenterologist, Psychiatrist and Nutritionist for optimal care. The mainstay of our dietary treatment should be to keep the patient

initially on a carbohydrate free diet for 6 weeks as carbohydrate is the only substrate that is converted to alcohol by fungi. Otherwise, these patients are at liberty to ingest any non-carbohydrate meal. A total elimination of carbohydrate is difficult to practice. We allowed small amounts of carbohydrate found in fruits or vegetables to be acceptable. Antifungal sensitivity testing should be done on any fungal strains isolated from the gastrointestinal secretions to determine the appropriate choice of antifungal treatment. We used nystatin as a first-line treatment when appropriate, as it has the least amount of side effects and an established safety record. Oral azole compounds (e.g., fluconazole and itraconazole) are our next drugs of choice if the patient is still symptomatic with elevated breath and blood alcohol levels while on nystatin therapy. Finally, intravenous micafungin is used for treatment failure.

In addition to antifungal therapy, these patients are started on a single strain probiotic (*Lactobacillus acidophilus*). Patients should continue to check their BAC twice a day during, and after the 6 weeks of antifungal treatment, and inform their physicians of any positive results. After successfully completing the 6-week therapy if the patient is asymptomatic with negative BAC, the antifungal therapy is gradually tapered during the next 6 weeks and then discontinued. We continued treatment with the probiotic long-term. It would be ideal to have the patient repeat the carbohydrate challenge test prior to reintroducing carbohydrate in their diet if feasible. If this test is positive then the patient would require further antifungal therapy.

Additionally, the role of probiotic use in ABS needs to be fully investigated. Probiotic strains of *Lactobacillus* have been studied and found to have inhibitory effects on biofilm formation and filamentation in *Candida albicans* species. This probiotic has also previously been shown to competitively inhibit gut fungal growth in patients.^{8,13-15} We had previously postulated that fecal microbiome transplant might be valuable in ABS patients. There has only been a single successful report of using fecal microbiome transplant for the treatment of ABS in Belgium. We await further studies on this treatment modality.¹⁷ See Figure 2 for proposed treatment algorithm.

(continued on page 20)

(continued from page 13)

CONCLUSION

ABS is a rare and underdiagnosed medical condition where ingested carbohydrate is converted to alcohol by fermentation in the gut. This condition should be considered in any patient who has signs and symptoms of inebriation despite denying alcohol intake. This syndrome has been described in the medical literature for over 50 years, but it still remains a condition with limited information regarding diagnosis and treatment. If a physician suspects that a patient has ABS, breathalyzer analysis during the symptomatic episodes could help the clinician determine if this condition might be present. We propose a standardized carbohydrate challenge test to screen patients with suspected diagnosis of ABS. While a positive test is very useful in detecting patients with ABS, a negative test does not definitively rule out ABS, as fungi could take longer than 24 hours to convert carbohydrate to alcohol. The seminal NIH microbiome study from 2007 using genetic methodology has found many fungi are undetected by our usual commercial laboratory culture techniques.^{15,17} As more research emerges on the gut microbiome, it is hoped that a better understanding of this medical condition will ensue. ■

References

- Ladkin RG, Davies JNP. Rupture of the stomach in an African child. *Br Med J. Br Med J.* 1948 Apr 3;1(4552):644.
- Iwata K. A review of the literature on drunken syndromes due to yeasts in the gastrointestinal tract. Tokyo, Japan: University of Tokyo Press; 1972.
- Hafez EM, Hamad MA, Fouad M, et al. Auto-brewery syndrome: ethanol pseudo-toxicity in diabetic and hepatic patients. *Hum Exp Toxicol.* 2017;36:445–50.
- Welch BT, Coelho Prabhu N, Walkoff L, et al. Auto-brewery syndrome in the setting of long-standing Crohn's disease: a case report and review of the literature. *J Crohns Colitis.* 2016;10:1448–50.
- Spinucci G, Guidetti M, Lanzoni E, et al. Endogenous ethanol production in a patient with chronic intestinal pseudo-obstruction and small intestinal bacterial overgrowth. *Eur J Gastroenterol Hepatol.* 2006;18:799–802.
- Green AD, Antonson DL, Simonsen KA. Twelve-year-old female with short bowel syndrome presents with dizziness and confusion. *Pediatr Infect Dis J.* 2012;31(4):425.
- Jansson-Nettelblatt E, Meurling S, Petrini B, et al. Endogenous ethanol fermentation in a child with short bowel syndrome. *Acta Paediatr.* 2006;95:502–4.
- Malik F, Wickremesinghe P, Saverimuttu J. Case report and literature review of auto-brewery syndrome: probably an underdiagnosed medical condition. *BMJ Open Gastroenterol.* 2019;6:e000325.
- Painter K, Cordell BJ, Sticco KL. Auto-brewery syndrome (Gut fermentation) [updated 2020 Jun 26]. In: StatPearls [Internet]. Treasure Island, FL: StatPearls Publishing; 2020 Jan-. Available from: <https://www.ncbi.nlm.nih.gov/books/NBK513346/>
- Yuan J, Chen C, Cui J et al. Fatty liver disease caused by high-alcohol-producing *Klebsiella pneumoniae*. *Cell Metabolism.* 2019;30:675–88.e7.
- Walker GM, Stewart GG. *Saccharomyces cerevisiae* in the production of fermented beverages. *Beverages.* 2016;2:30.
- Tameez Ud Din A, Alam F, Tameez-Ud-Din A, et al. Auto-brewery syndrome: a clinical dilemma. *Cureus.* 2020;12:e10983.
- Cordell B, McCarthy J. A case study of gut fermentation syndrome (auto-brewery) with *Saccharomyces cerevisiae* as the causative organism. *Int J Clin Med.* 2013;04:309–12.
- Suez J, Zmora N, Zilberman-Schapira G, et al. Post-antibiotic gut mucosal microbiome reconstitution is impaired by probiotics and improved by autologous FMT. *Cell.* 2018;174(6):1406–1423.e16.
- Vilela SFG, Barbosa J, Rossoni R, et al. *Lactobacillus acidophilus* ATCC 4356 inhibits biofilm formation by *C. albicans* and attenuates the experimental candidiasis in *Galleria mellonella*. *Virulence.* 2016;6:29–39.
- Vandekerckhove E, Janssens F, Tate D, et al. Treatment of gut fermentation syndrome with fecal microbiota transplantation. *Ann Intern Med.* 2020;173(10):855.
- Sam QH, Chang M, Chai L, et al. The fungal mycobiome and its interaction with gut bacteria in the host. *Int J Mol Sci.* 2017;18(2):330.

